
Permanent hair removal of white, grey and light blond hair after laser treatment combined with melanin encapsulated liposomes. (Lipoxôme®)

Jaap de Leeuw, MD, Nick van der Beek, Dieter Neugebauer, MD,

*MULTICARE, CLINIC FOR DERMATOLOGY AND LASER TREATMENT,
HILVERSUM, THE NETHERLANDS.*

Summary:

Melanin in the hairfollicle is the chromophore for selective photothermolysis of unwanted hair. Photothermolysis is not effective in people with white, grey and light-blond hair because melanin is lacking in their follicles. In this article we describe that in these persons good results can be obtained through liposome-targeting of melanin into the hairfollicles prior to lasertreatment.

Abstract: Until now, people suffering from unwanted, non-pigmented hair grow (white, grey and light blond) could not effectively been treated by photothermolysis. Melanin encapsulated liposomes are able to target melanin into the hair follicle.

Melanin is the primary chromophore for laser hair removal. The external application of these liposomes prior to laser treatment ables to achieve permanent hair removal.

Objective: Monitoring the efficacy of lasers and intense pulsed light sources when used for the permanent hair removal with the use of melanin encapsulated liposomes (Lipoxôme®). 40 patients suffering from unwanted, non-pigmented hair grow (white, grey and light blond) were treated with a diode laser once every 6-8-weeks after external application of melanin encapsulated liposomes.

Results: 40 patients with white, grey and light blond hair in the face (hirsutism) have been treated with a Diode Laser. Melanin encapsulated liposomes (Lipoxôme®) were applied to the treatment area, 6 to 8 times a day, during the 14 days prior to the laser treatment. Six months after the last lasertreatment, most patients (90.0%) had considerable hair reduction (75-100 %). 62,5 % of the patients achieved a permanent hair reduction between 95 - 100%. Photographs were taken before, during and at the end of treatment(**fig.a,b**)

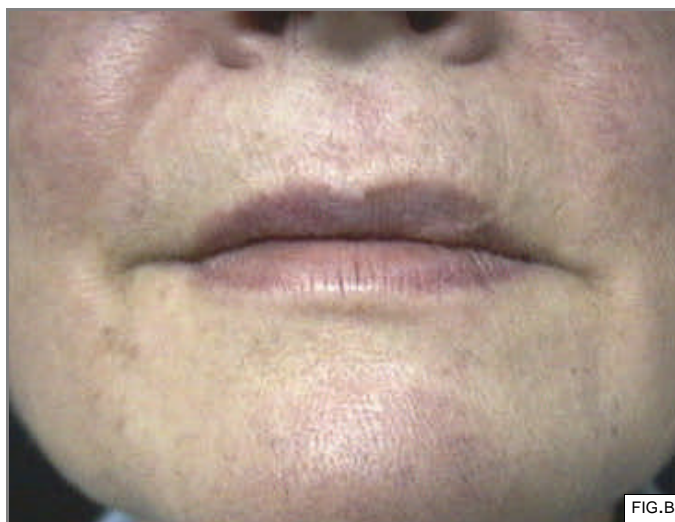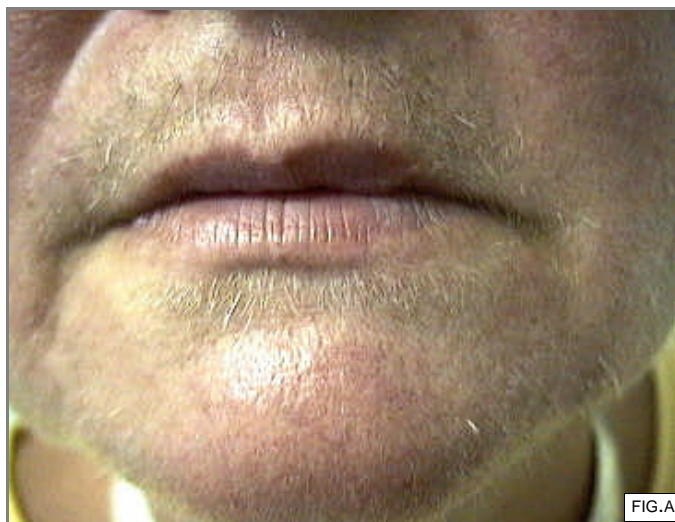Introduction

Unwanted facial and body hair can represent a severe cosmetic disturbance with social and psychological implications often strong enough to motivate patients, especially women, to seek dermatological treatment. The phenomenon of unwanted hair can be divided into three main categories:

Hypertrichosis is excessive hair in a normal distribution or in abnormal locations. The cause of universal hypertrichosis is most commonly genetic and often seen in Caucasian women from the Mediterranean and

Middle East. Hypertrichosis can also occur as a secondary effect of endocrine and metabolic disturbances, from medication side effects, tumors, neurological diseases, anorexia nervosa and various dermatological entities as Becker's nevi and congenital nevi.

Hirsutism describes hair growth in women in a male pattern distribution. This occurs as idiopathic hirsutism



or secondary to polycystic ovary disease, ovarian tumors, adrenal abnormalities, hyperprolactinemia, acromegaly, and androgen therapy.

Aesthetic reasons due to cosmetic demands in our society, in which it is undesirable to exhibit hair growth on certain areas. Many women desire hairless legs, axillae, and inner thighs, some men want to remove hair growing on their back and shoulders.

Patients with hirsutism and hypertrichosis need medical examination for, and if necessary, treatment of underlying diseases. Whether treated or not the wish for hair removal mostly remains.

Until now, several methods have been used to remove superfluous hair. Shaving, plucking, waxing and chemical depilation are effective in the short term, but not in the long term. Anti-androgen drugs as cyproteronacetate can be effective, although side effects are possible and hair growth returns after stopping the use of the drug.

Electrolysis and thermolysis are the only histological proven permanent methods of epilation, but these techniques are time consuming, painful, prone to scarring and infection, impractical for treating large areas and hair regrowth is variable, ranging from 15% to 50%⁽⁸⁾.

Photothermolysis and thermokinetic selectivity

The use of melanin-based selective photothermolysis has paved the way to new non-invasive modalities for hair removal. ^(1,2,6)

Selective photothermolysis predicts that thermal injury will be restricted to a given target if:

- The wavelength of the light source corresponds to the absorption peak of the target.
- The pulse duration is shorter than the thermal relaxation time of the target. ^(5,7)

At the present time, the primary chromophore for laser hair removal is melanin residing in the hair shaft.

Melanin absorbs broadly across the optical spectrum. The competing chromophores, oxyhemoglobin and water, absorb less energy at wavelengths between 690 and 1000 nanometer.

Therefore, any light source (laser or intense pulsed light source) that operates between 690 and 1000 nm is appropriate for targeting melanin in the hair shaft.

Melanin absorbs better at 694 nm than at longer wavelengths, but penetration of light is deeper with longer wavelengths. The complicating factor in selecting melanin, as the target for laser hair removal is that melanin is also found in the epidermis. In consequence there may be damage to the epidermis and absorptive interference by epidermal melanin.

This problem can be overcome by using of thermokinetic selectivity, which is based on the fact that large targets retain heat longer than small targets of the same chromophore.

High energies required to damage a large target would

spare a smaller structure, if the energy is infused for a period that exceeds the required time for the small structure to release its absorbed heat.

The ideal pulse duration should therefore be between the thermal relaxation time (TRT) for the epidermis (3-10 msec) and the TRT for the hair follicle (40-100 msec). It seems that pulse durations between 10 and 50 milliseconds are optimal for destroying hair follicles while minimizing undesired epidermal injury.

The conduction of heat from the shaft ultimately damages the hair follicle. Heating of the hair shaft alone results in temporary epilation due to induction of an anagen to telogen shift. Sufficient follicular damage is necessary to achieve permanent hair reduction and this needs an adequate fluence. Effective light sources deliver fluences up to 50 J/cm². The light treatment can only be effective if the shaft is present, so the patient should not epilate 6 weeks prior to treatment.

The growth of human hair is unsynchronised cyclic in all body sites. All hairs go through a cycle of active growth (anagen), transition (catagen), and resting (telogen) stage. During anagen the melanocytes in the lower hair bulb actively transfer melanin to the dividing population of matrix cells. At the end of the anagen stage melanization ceases and lower matrix keratinocytes cease proliferation and undergo terminal differentiation resulting in involution of the lower follicle. The follicular bulb moves up superficially in the dermis, the dermal papilla moves toward the bottom of the regressing follicle.

This means, that active melanin distribution as well as full contact with all structures of the follicle, that may give raise to new hairs, only occurs during anagen and not during telogen.

The many patients, who have blond, white, grey and light-blond hair cannot effectively be treated by photothermolysis.

Liposomes

Phospholipids are biologic membrane lipids who spontaneously adopt bilayers in water. This ability is due to their amphipathic character, resulting from the presence of a polar or hydrophilic (water-loving) head group region and a nonpolar, hydrophobic (water-hating) region.

In the presence of water the hydrophilic head groups orient toward the aqueous phase and the nonpolar regions are sequestered from water.

Phosphatidylcholine (PC) is the class of phospholipid most commonly used to construct liposomes for drug delivery. When PC is hydrated, macromolecular structures are formed which consists of multiple bilayers arranged as concentric rings separated by narrow aqueous spaces.

Hydrophilic drugs can be trapped in the aqueous phase and lipophilic drugs in the lipid phase ⁽⁴⁾.

Melanin encapsulated liposomes have been selectively targeted to the hair follicle and hair shafts of mice. Negligible amounts of delivered molecules enter the dermis, epidermis, or bloodstream thereby demonstrating selective follicle delivery. Liposome targeting of melanin to hair follicles has also been achieved in human scalp and the ability to colour hair with melanin has been demonstrated. ⁽³⁾

Materials and methods

After informed consent, 40 adult patients, 38 female suffering from idiopathic hirsutism and two male with hypertrichosis one on his back and one disabled patient who could not shave himself, were treated with a diode laser. The average age was 48 years, (range 28-75). Mean duration of the discomfort was 29 years (range 10-57). All patients had been treated before with all possible treatment modalities as electrolysis, laser, etc, without any notable hair reduction. The Laser (Diode 800 nm, 10-40 J/cm²) has a spot size from 9x 9 mm. The pulseduration is 5-30 msec. A fluence range of 25 - 30 J/cm² for the face and 40 J/cm² for the body was used for this study.

Exclusion criteria were: pregnancy and breastfeeding, photosensitive disorders and malignant skin diseases. Only patients with white, grey and light-blond hair, who were resistant to any other treatment option, were included in the study. They followed standard after care. Patients were also requested to report any complication immediately. They returned for evaluation and follow up treatment at 6 - 8 weeks interval. Patients could discontinue treatment at any time. The patients were instructed to apply a spray containing melanin encapsulated in phosphatidylcholin based liposomes (Lipoxôme®) 6 - 8 times a day, 14 days prior to the laser treatment. Photographs (Fotofinder, TeachScreen Software GmbH, Germany), of the subjects were taken at the beginning, during, and at the end of the therapy. These photographs provided a base measure for evaluation of the treatment efficacy. Photographs and subjective grading were executed by experienced physicians. Improvement was graded on the following weighted scale:

- 1 = 0 - 49% improvement,
- 2 = 50 - 74%,
- 3 = 75 - 94%
- 4 = 95 - 100%

Control group

Twenty female patients suffering from the same discomfort, as the study group, (idiopathic hirsutism) and having white, grey and light blond-hair, were selected as a control group. They were only treated with the laser (Diode 800 nm, 10-40 J/cm²), but without the use of the melanin liposomes. They underwent at least four laser treatments per patient with an interval of 6-8 weeks. At the last control visit, six months after the last laser treatment these patients hardly showed any notable hair reduction.

Histological Study

For this study skin biopsies were taken from both arms of 5 persons with non-pigmented hair. One arm was pre-treated with Lipoxôme® 6 to 8 times a day during 14 days. The slides were stained according to Schmorl's reaction (TNO, The Netherlands). Photographs were taken of the slides of both arms. In contrast to the sites that were not treated with melanin containing liposomes (**fig.c**), the pre-treated sites (**fig.d**) exhibit clearly deposits of melanine.

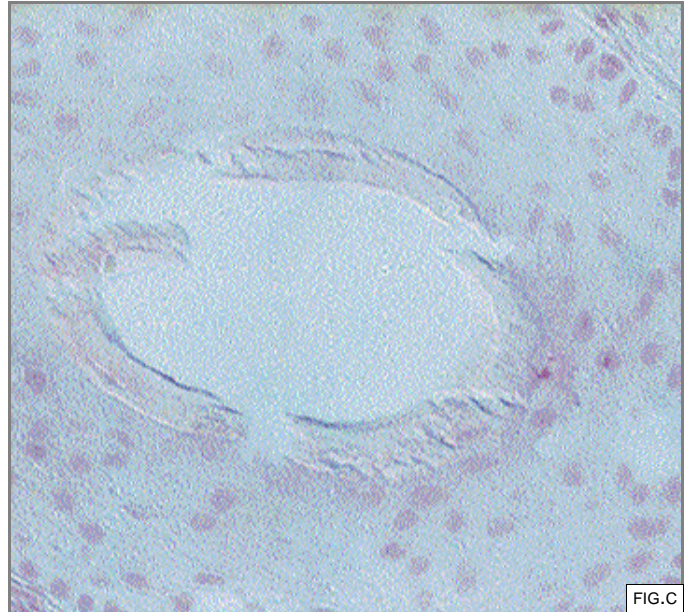

FIG. C

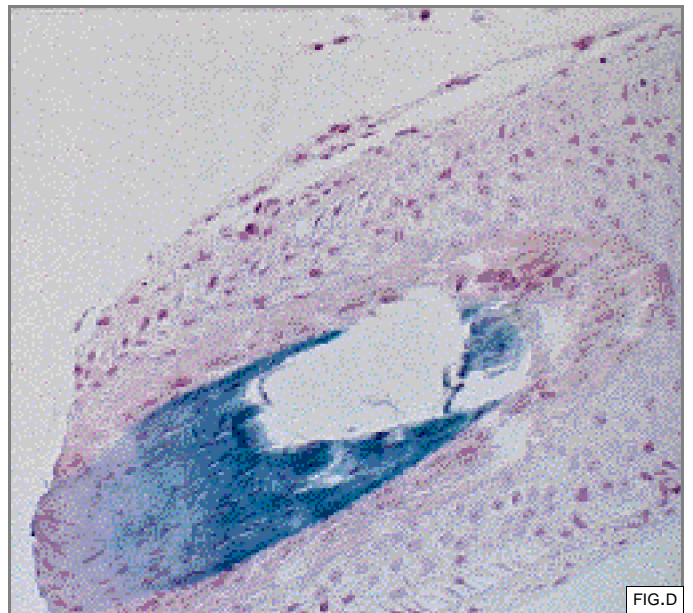


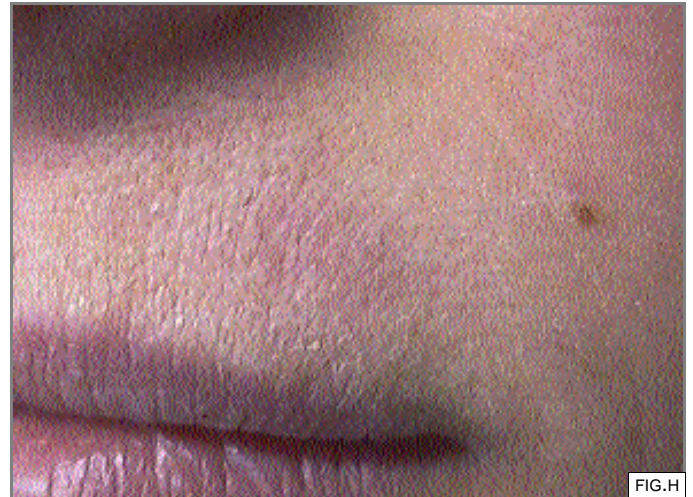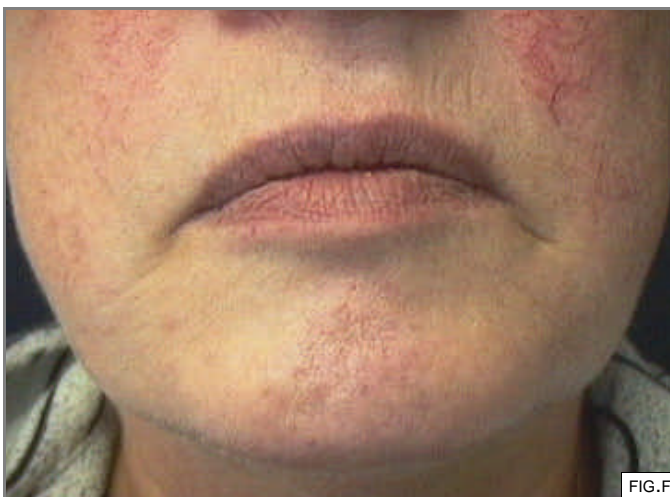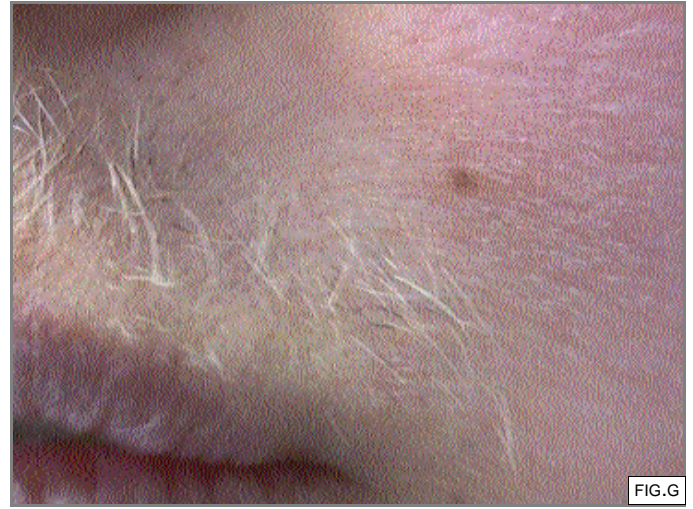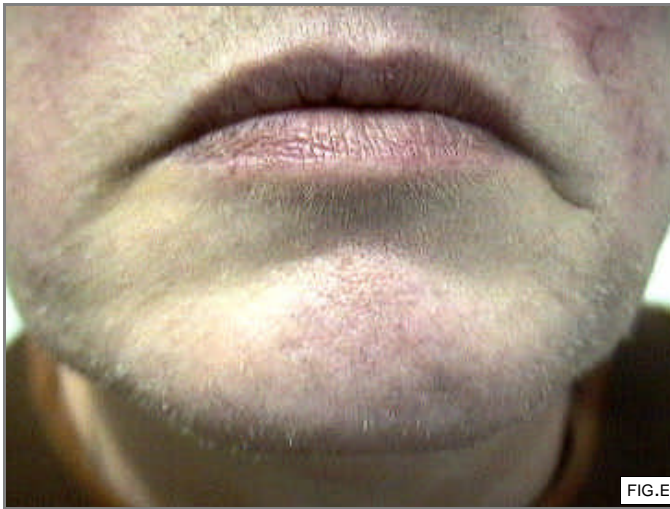FIG. D

Histology responses to laser treatment

There are three distinct responses that account for an apparently permanent reduction of pigmented, coarse hair:

- miniaturization of hair follicles
- decreased pigmentation of regrowing hair
- degeneration of hair follicles with replacement by fibrosis. Permanent hair loss is defined as significant and stable loss of hair for a period longer than the complete natural hair growth cycle.

Hair removed	Average quantity of Lipoxôme® used before treatment in ml
0-49%	19
50-74%	31
75-94%	59
95-100%	109



Results:

40 patients with white, grey and light blond hair in the face (hirsutism) have been treated with a Diode Laser in combination with melanin-encapsulated liposomes. Lipoxôme® was applied to the treatment area 6 to 8 times a day, during the 14 days prior to the laser treatment. Photographs were taken before, during and at the end of treatment. (fig.e,f,g,h)

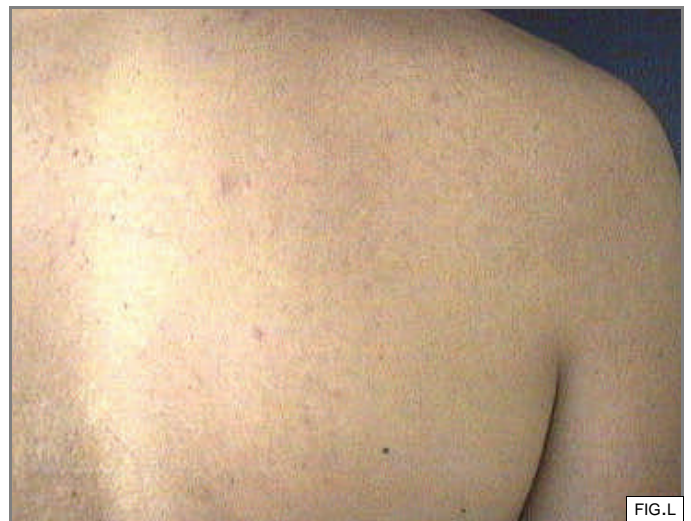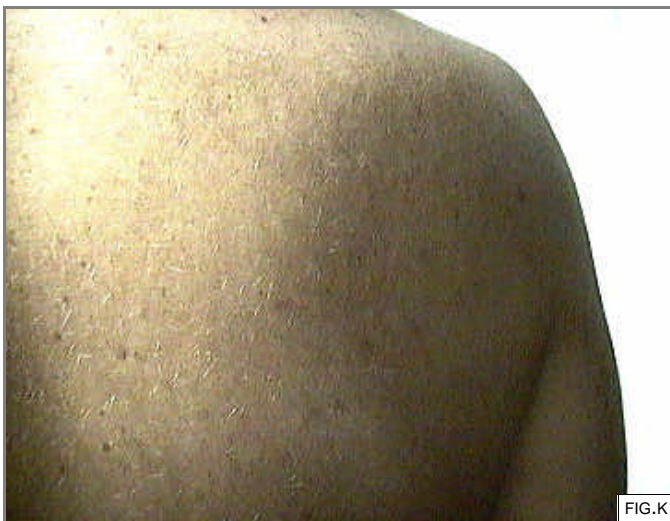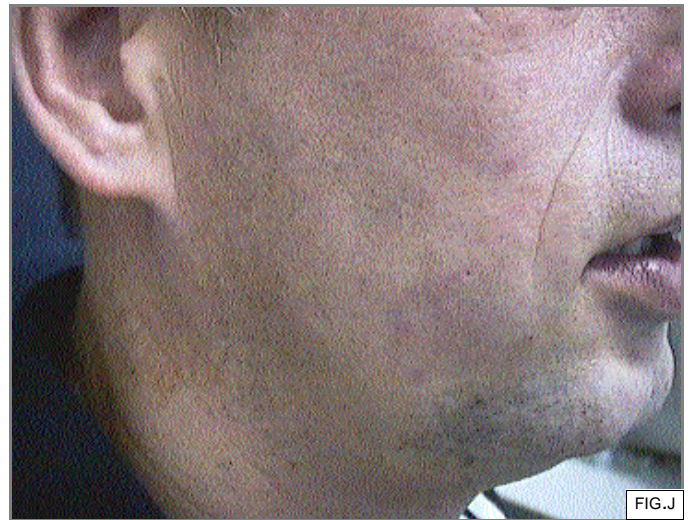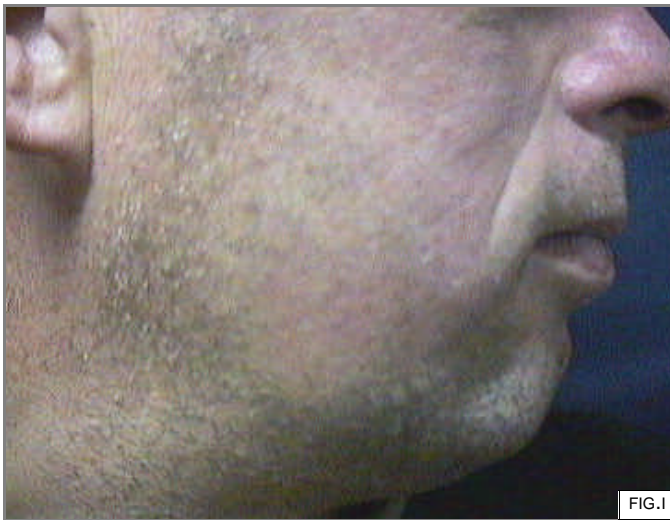Six months after the last laser-treatment, 90% of the patients experienced a permanent hair reduction of over 75% within 10 treatments, with an average number of 7 treatments. 62,5% of the patients even experienced a hair reduction of 95% or more with an average of 8 treatments.

The quantity of Lipoxôme® applied to the area before treatment turned out to be a crucial factor for the success of the treatment. All patients who used more than 86 ml of Lipoxôme® per treatment experienced a hair reduction of 95% or more.

The patients who experienced a hair removal of 95% or more used 109 ml on average. There was a significant correlation between the quantity of hair reduction and the average quantity of Lipoxôme® used prior to every treatment of 0,785 at a significance level of 99,9%. This shows that there is a very strong relation.

There was no statistical evidence of a relationship between the percentage of hair removed and other factors, such as hair colour, number of treatments or energy used.

It can be concluded that the application of Lipoxôme was crucial for the success of the hair removing treatment. The patients with the best results regularly applied a quantity of 109 ml of Lipoxôme per treatment on average. The statistical analysis clearly shows that more Lipoxôme used leads to more hair removed. (fig.i,j,k,l)



Side effects

Side effects from hair laser treatment are transient discomfort, redness, perifollicular edema and crusting. Hyper- and hypopigmentation may occur and will disappear spontaneously in weeks to months. Local blisters may occur at high fluences in patients with a dark skin. Cooling the skin during treatment is an important tool to diminish epidermal side effects and has also some anaesthetic properties.

Conclusion

The effectiveness for permanent hair reduction is strongly correlated with hair colour. Patients with, white, grey and light-blond hair are unlikely to experience a permanent reduction in hair with only laser or light treatment. In these persons good results can be obtained by using melanin encapsulated phosphatidylcholine-based liposomes (Lipoxôme®), which have a high potential for selectively targeting the melanin into the hair follicles, prior to laser or light treatment. The results in persons with less pigmented hair can be optimised in the same way.

Although the correlation between the use of the melanin-liposomes and the treatment results is significant, the problem in home treatment is the lack of control of patients' compliance. Particular patients showing good results at the beginning of the treatment are likely to reduce the application of the liposomes, this has a negative impact on the laser-treatment results.

Acknowledgements

MultiCare thanks dr. Brian D. Zelickson MD and the department of Dermatology, University of Minnesota, Minneapolis, USA for their assistance.

MultiCare Medical Services b.v.
Hoge Naarderweg 7H
1217 AB Hilversum
The Netherlands
Phone: 0031356249576
Fax: 0031356246707
E-mail: Multicare@planet.nl

Literature:

1. Dierickx CC, Grossman MC, Farinelli WA, Anderson RR "Permanent hair removal by normal-mode ruby laser" Arch. Dermatol. 134: 837-842, 1998.
2. Grossman MC, Dierickx CC, Farinelli WA, Flotte TJ, Anderson RR "Damage to hair follicles by normal-mode ruby laser pulses" J. Amer. Acad. Dermatol 35: 889-884, 1996.
3. Hoffman RM "Topical liposome targeting of dyes, melanins, genes and proteins selectively to hair follicles" J. of Drug Targeting 3(2): 67-74, 1997.
4. Hope MJ, Kitson CN "Liposomes, a perspective for dermatologists" Dermatol. Clinics 11, nr.1 143-153, 1993.
5. Lask G "Laser-assisted hair removal by selective photothermolysis" Dermatol Surg 23: 737-739, 1997
6. Lou WW, Quintana AT, Geronemus RG, Grossman MC "Prospective study of hair reduction by diode laser (800 nm) with long-term follow-up" Dermatol Surg 26: 428-432, 2000.
7. Nestor MS "Laser hair removal: clinical results and practical applications of selective photothermolysis" Skin and Aging: 34-41, jan 1998.
8. Olsen A. "Methods of hair removal" J. Amer. Acad. Dermatol 40: 143-155, 1999.